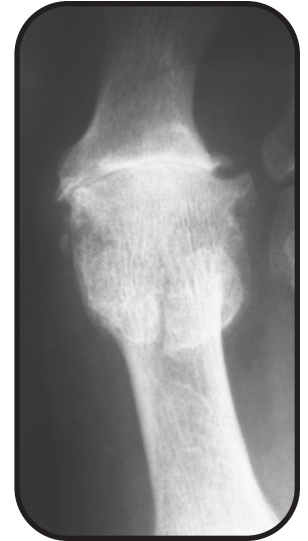

Hallux Metatarsophalangeal Joint Fusion

V. James Sammarco, MD
Cincinnati Sports Medicine and Orthopaedic Center
Cincinnati, OH

Clinical Presentation


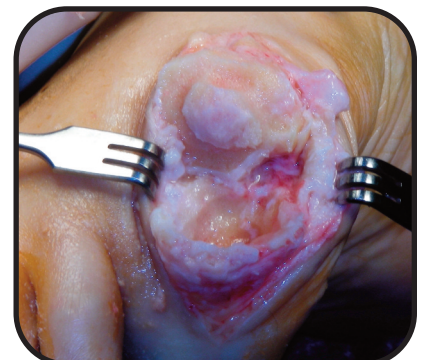
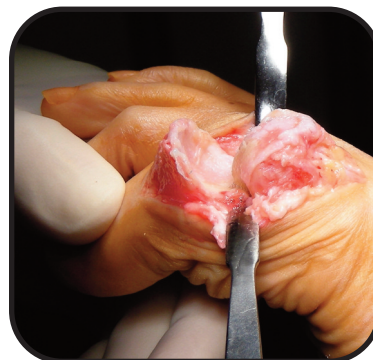
A fifty-five year old male presented with severe pain due to arthritis of the hallux metatarsophalangeal joint. Physical examination showed loss of motion, large osteophytes and pain with axial loading of the joint. Radiographs showed complete loss of articular cartilage and large peripheral osteophytes - end stage arthritis of the Hallux Metatarsophalangeal Joint (MTP). Arthrodesis of the joint was planned.



Surgical Management

A dorsal approach was used over the hallux metatarsophalangeal joint with dissection carried out medial to the extensor hallucis longus tendon. The capsule was incised and a synovectomy performed. A subperiosteal dissection exposed the metatarsal head and base of the proximal phalanx. Plantarflexion of the joint allows excellent visualization.

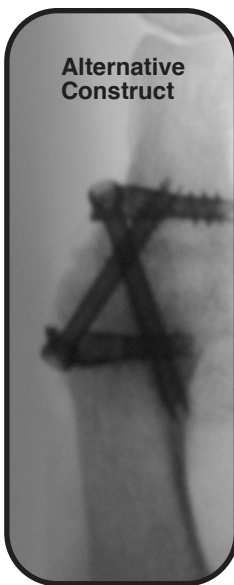
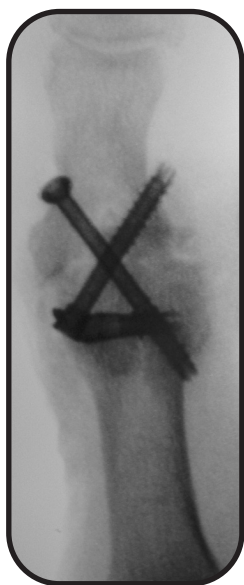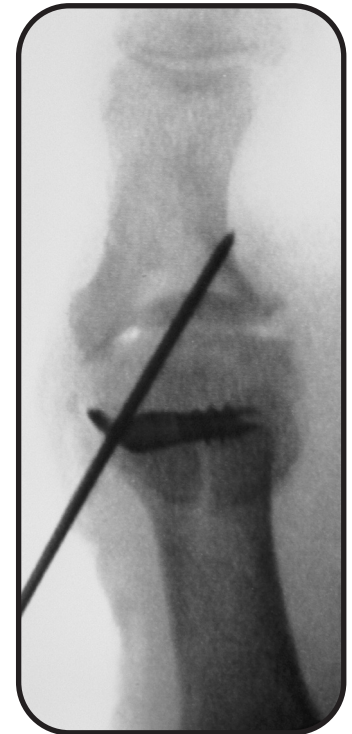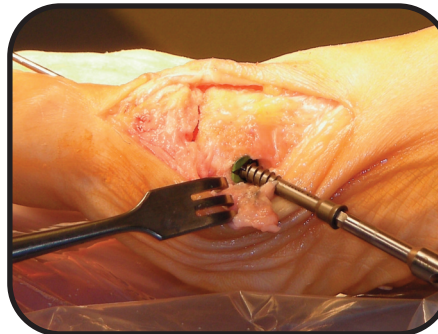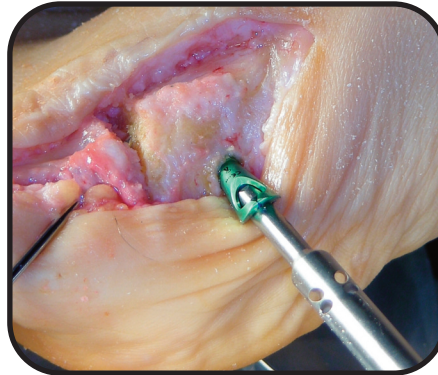
Preparation of the bone was done in this case creating a "cup-in-cone" arthrodesis bed with a 5mm burr. After the removal of cartilage, the head is shaped so that the cancellous bone of the metatarsal head invaginates into the base of the proximal phalanx. Conical reamers are now available from Extremity Medical for this purpose.



For best push off, the hallux was positioned in slight dorsal flexion so that approximately 5mm of clearance was present between the pulp of the Hallux and the floor. Slight valgus angulation (5° – 15°) of the entire digit must be fine tuned for each patient. There should be a few millimeters of clearance between the hallux and second ray and the digit should be placed at a neutral axial rotation with the plane of the floor. Positioning is provisionally held with a K-Wire. Positioning is best checked by pressing a flat plate against plantar aspect of the foot.

The X-Post of this device is applied over a guidewire in the first metatarsal head. The Post should be orthogonally positioned to the arthrodesis bed. The compression screw is then applied into the base of the proximal phalanx. Verify positioning of the guidewire for the cannulated compression screw with fluoroscopy prior to screw insertion. Rigid compression of the arthrodesis was achieved with this IO-FiX construct. A tapered compression screw was utilized to create a stable fixed angle construct once it was fully engaged.

Additionally, a cannulated screw was utilized as a second point of fixation to ensure rotational stability. Alternately, another IO-Fix device may be applied with the Post in the proximal phalanx and the cannulated compression screw applied into the metatarsal.



Outcome

Post-Operatively, the patient was allowed to weight bear on their heel after 10 days in a post-operative shoe, and then allowed to walk flatfooted after radiographic healing (typically four to six weeks).

This patient healed the arthrodesis after five weeks and was able to return to normal footwear after 6 weeks.

