

### Multiple Tarsometatarsal Fusion

Brian Donley, MD

Director of the Center for Foot and Ankle  
In the Orthopaedic and Rheumatologic Institute  
at the Cleveland Clinic

#### Clinical Presentation

Patient is a 56 year old woman diagnosed with midfoot arthritis. She had complained of increasing pain over a 2 year time period. Several non-operative treatments had failed including the use of anti-inflammatory medications and custom orthotics.

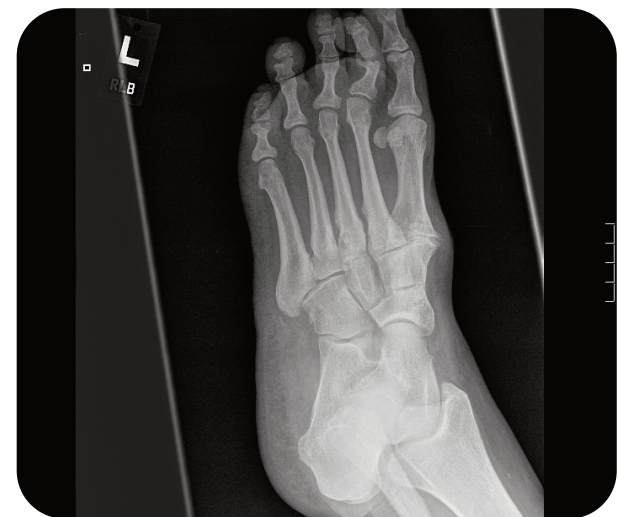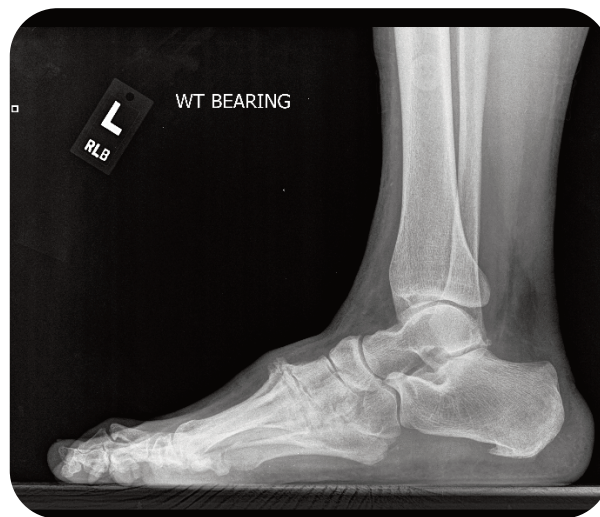
#### Surgical Management

A midfoot fusion of the 1st, 2nd and 3rd TMT joints was performed utilizing three IO FiX constructs (4.0mm Lag Screw). See the Extremity Medical IO FiX Surgical Technique Guide for details on this procedure.

#### Outcome

The patient is now 3 months out. All joints have fused solidly. She is weight bearing as tolerated without pain and reports to be doing well.

Pre-op



Post-op (12 weeks)

