

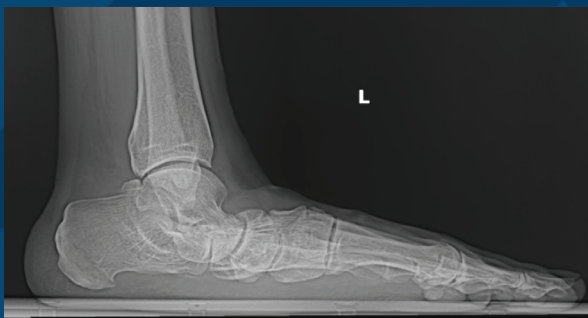## Talonavicular Arthrodesis For Correction of Rigid Progressive Collapsing Foot Deformity

**S. Blake Wallace, MD**  
Plano Orthopedic and Sports Medicine Center  
Plano, TX

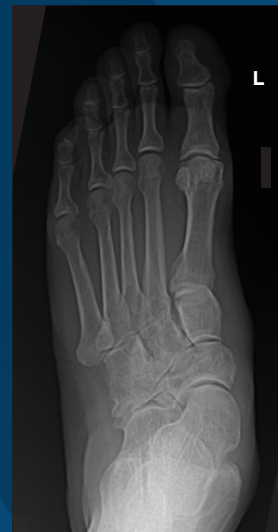### Clinical Presentation:

This 70 year old man presented with a severe progressive collapsing foot deformity of the left foot with daily pain along the medial foot and ankle. He attempted physical therapy, custom orthotics, bracing, and immobilization in a walking boot, but continued to have pain. He had not had any prior surgeries to this foot or ankle. Past medical history was significant for depression, hypertension, and hyperlipidemia which were controlled with medications.

### Preoperative:



(a.)



(b.)

**Figure 1:** Preoperative X-Ray of the foot in (a) lateral and (b) AP views, showing severe progressive collapsing foot deformity.

## Surgical Management

It was decided to proceed with a talonavicular and subtalar arthrodesis, 1<sup>st</sup> tarsometatarsal arthrodesis with an allograft wedge, deltoid ligament repair, and gastrocnemius recession. For a combined subtalar and talonavicular arthrodesis, the surgeon's preference was to (1) prepare both joints for arthrodesis, (2) temporarily fixate the talonavicular joint, (3) place final fixation

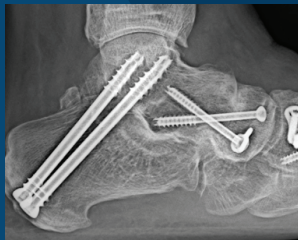in the subtalar joint, and (4) place final fixation in the talonavicular joint. Intraoperatively there was significant osteoporosis of the medial talar head and the medial navicular. After this sequence was completed, there was significant forefoot supination which was addressed with a 1<sup>st</sup> TMT joint fusion using an allograft wedge. This report will focus on the technique for the talonavicular arthrodesis.

## Talonavicular Arthrodesis Technique:

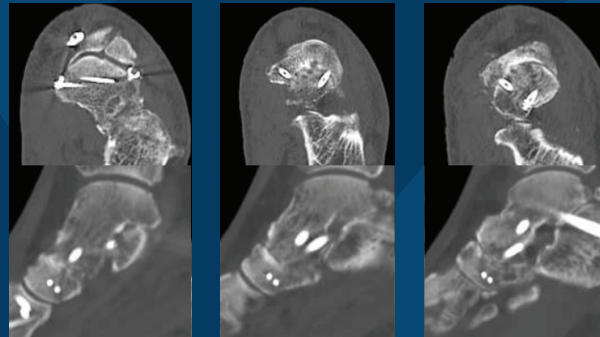
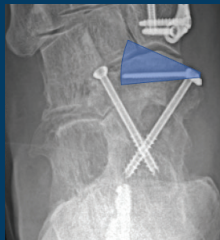After joint preparation, the joint was provisionally pinned in the desired position. Next, the ideal paths for the two compression screws were chosen perpendicular to the joint. Both guidewires for 4.5mm screws were placed to ensure there would be no interference within the talar neck. The countersink was used to ensure the X-Post would not be prominent medially. The plantar medial screw was then placed. As the screw was advanced, the stop washer was applied, which stopped the screw at the appropriate distance from the cortex to allow for placement of the IO Freedom X-Post. Once the stop washer was engaged, it was removed. The drill guide for the IO Freedom X-Post was placed over the screw. The drill was then placed into the drill guide and the trajectory was confirmed with fluoroscopy prior to drilling. The guide allowed for easy adjustments to the trajectory in all planes, so the ideal pathway was expeditiously identified before drilling into the bone. The angle between the screw

and the post can be as high as 80° and as low as 55°. Figure 2a demonstrates the zone of potential placement for the medial X-Post based on the screw position. After the first hole was drilled, the drill was left in place and a second drill used to allow for fluoroscopic confirmation that the holes were parallel and had not skived. Laser lines on the drills allowed for post length measurement. For this case, the longest available X-Post (30mm) was placed and directed slightly plantar. Prior to final tightening of the medial IO Freedom device, a dorsolateral 4.5mm compression screw was placed through a small incision. The plantar medial screw had excellent bite, despite significant osteopenia. The implant was not prominent medially. Fluoroscopy and direct visualization confirmed compression throughout the entire joint. A compression screw was inserted laterally in conjunction with the IO Freedom construct medially, to prevent the joint from gapping laterally.

## Postoperative:



(a.)



(b.)

**Figure 2:** Postoperative imaging showing (a) X-Rays at 6 months and (b) CT at 6 weeks. The AP view in Figure 2a. demonstrates the zone of placement for the medial X-Post based on the screw position.

Postoperatively, the patient was made non-weight bearing for six weeks, and CT was obtained to confirm union of the arthrodesis sites (Figure 2b). At that point he had clinically and radiographically healed the arthrodesis sites. He was then made weightbearing in a

boot for four weeks to protect the concomitant deltoid ligament repair, and then was transitioned to regular shoes. After six months, follow up radiographs showed union at the arthrodesis site. He was able to walk in normal shoes without pain.

## Conclusion

In the author's experience, the IO Freedom X-Posts are versatile and allow for excellent compression, even in osteoporotic bone, acting as an intraosseous washer. The sequence of placement allows for the X-Post to be added to the compression screw after it is partially placed. Thus, if an isolated screw is placed and there is insufficient purchase in the near cortex, the screw can be backed up partially, and the IO Freedom X-Post can be added for additional purchase. The variable angle between the X-Post and the screw gives the surgeon freedom to place both in the ideal position for maximal compression.

# IO Freedom™

Fusion Fixation

**Delivering**  
a smarter approach for fusion.  
**Period.**

Challenging cases. Better outcomes.  
**Real change starts here™**

**EXTREMITY®**  
MEDICAL

Real change **starts here™**

888.499.0079

973.588.8980

ExtremityMedical.com

customerservice@ExtremityMedical.com

300 Interpace Parkway, Building A, Floor 2 | Parsippany, NJ 07054 | [www.ExtremityMedical.com](http://www.ExtremityMedical.com)

© 2023 Extremity Medical, LLC. All Rights Reserved. Extremity Medical®, and IO Freedom™ are trademarks of Extremity Medical, LLC.

MKT-147-00001 Rev A 03/2023